

La vérité sur l'oncocyte

Les révélations moléculaires

Club thyroïde Ile de France

Pr Lionel Groussin

Hôpital Cochin

Université de Paris

Samedi 18 septembre 2021, hôpital Cochin

Biologie moléculaire cancers de la thyroïde

Cancer papillaire - peu différencié - anaplasique

Dan L. Longo, M.D., Editor

Biologic and Clinical Perspectives on Thyroid Cancer

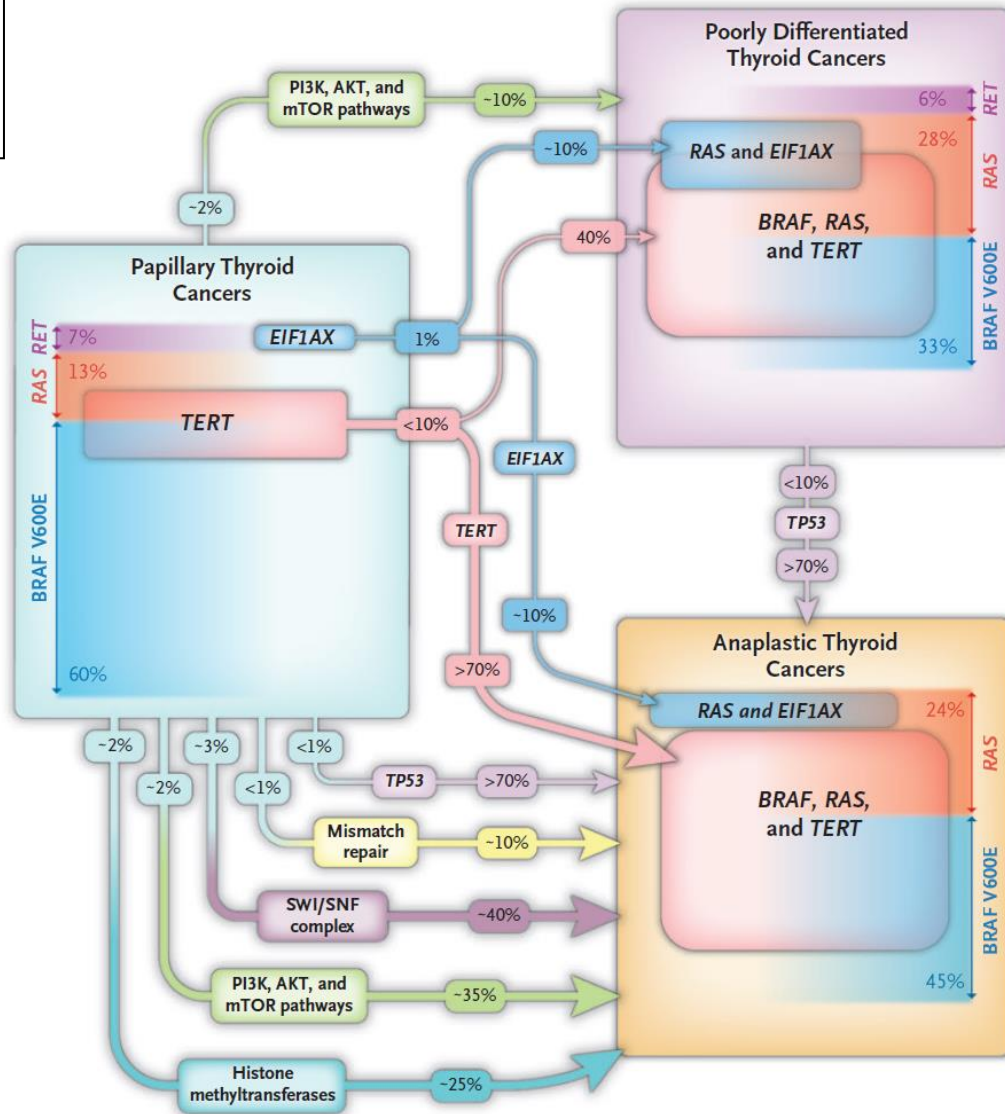
James A. Fagin, M.D., and Samuel A. Wells, Jr., M.D.

- « Drivers »
- Voie MAPK
- Mutuellement exclusif

Voie MAPK
Récepteur TK
RAS
BRAF^{V600E}

Anomalies II^{aires}

- TERT
- TP53
- EIF1AX
- ...



Cancer oncocytaire (HCC)
 ?

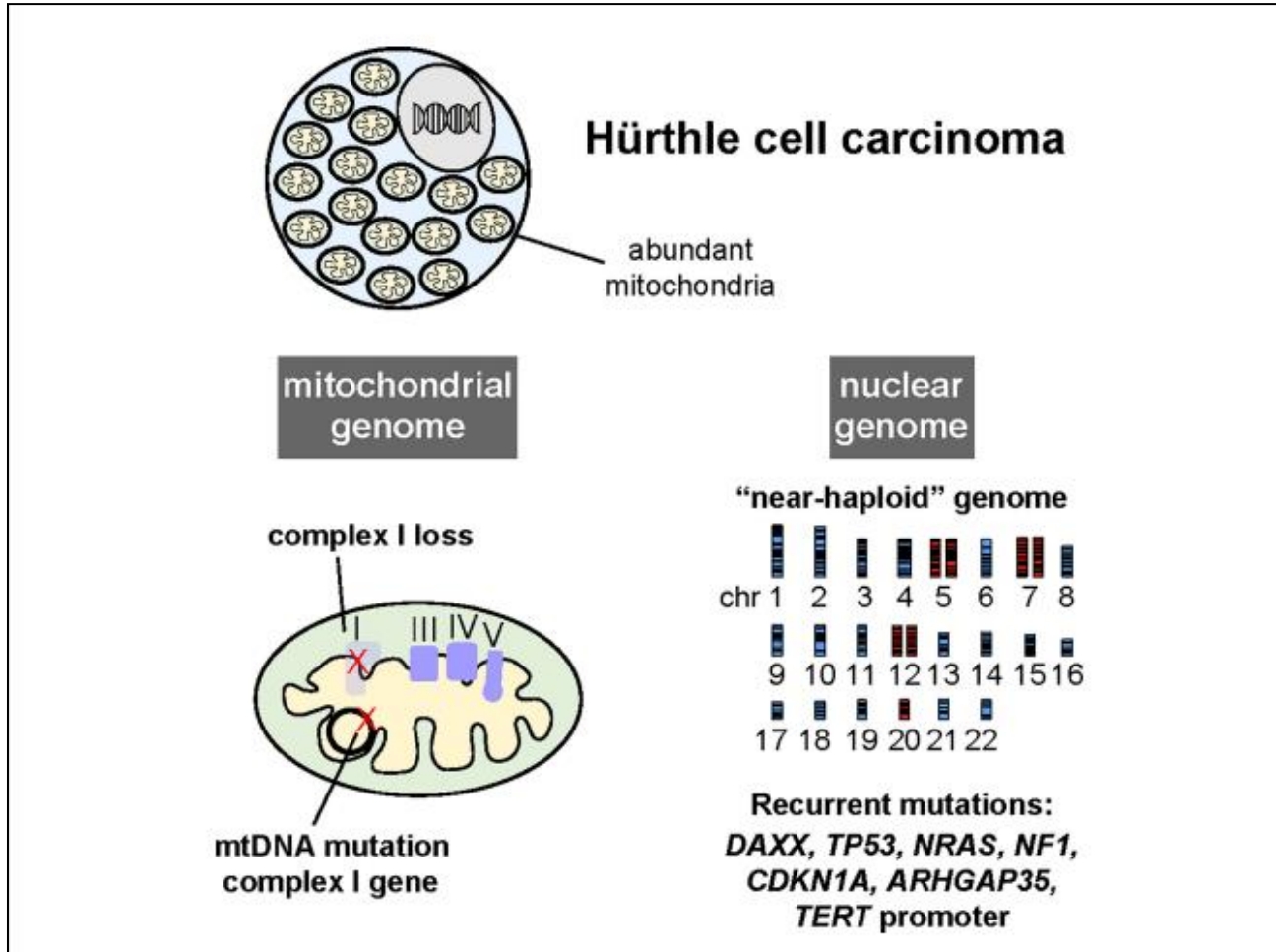
Biologie moléculaire cancers oncocytaires thyroïdiens

Messages...

- Pas une forme cancer vésiculaire = entité part entière
- Peu anomalies communes avec cancers papillaires et vésiculaires
- Taux élevé **mutations mitochondriales**
Mutations **complexe I** chaîne respiratoire
Dysfonction mitochondriale
Apparition tumeur, pas de rapport avec agressivité
- **Glycolyse aérobie**, pas phosphorylation oxydative
- Captation forte glucose (FDG PET +++), faible activité respiratoire
- **augmentation traduction protéines** (EIF1AX...), rôle mTOR
- Gènes de fusion spécifiques
- **Duplication chromosomes et disomie uniparentale**

Biologie moléculaire cancers oncocytaires thyroïdiens

Messages...



Tumeurs sensibles ?

- à hypoxie
- à hypoperfusion

Disparition, modification après:

- Traumatisme, particulièrement si hémorragie
- cytoponction....
- palpation...

Génétique tumeurs oncocytaires thyroïdiennes

Gène prédisposition
familiale

Altérations
somatiques



Cancer Cell 2018

Memorial Sloan Kettering Cancer Center

Prédisposition germinale

Correia et al.

Inherited Thyroid Tumors With Oncocytic Change

Thyroid tumor histotype	Inheritance	Locus	Candidate gene
Individuals from one family affected with multinodular goiter and papillary thyroid carcinoma, with and without cell oxyphilia	Germline (autosomal dominant)	TCO	Linkage to a gene on 19p13.2 – TCO locus
Oncocytic thyroid carcinomas (follicular and papillary)	Germline and somatic	TCO	GRIM-19
Individuals from families affected with thyroid tumors with and without cell oxyphilia	Germline and somatic	TCO	TIMM44
Two oncocytic thyroid carcinomas and one oncocytic thyroid adenoma	Germline	TCO	MYO1F

GRIM19= protein chaperone complex I chaine respiratoire

TIMM44 = Translocase of Inner Mitochondrial Membrane 44

MYO1F= Myosin-IF

Integrated Genomic Analysis of Hürthle Cell Cancer Reveals Oncogenic Drivers, Recurrent Mitochondrial Mutations, and Unique Chromosomal Landscapes

Ian Ganly,^{1,2,*} Vladimir Makarov,^{1,3} Shyamprasad Deraje,¹ YiYu Dong,¹ Ed Reznik,^{4,5} Venkatraman Seshan,⁴ Gouri Nanjangud,⁶ Stephanie Eng,¹ Promita Bose,¹ Fengshen Kuo,¹ Luc G.T. Morris,^{1,2} Inigo Landa,¹ Pedro Blecua Carrillo Alborno,^{1,3} Nadeem Riaz,^{1,3} Yuri E. Nikiforov,⁷ Kepal Patel,⁸ Christopher Umbricht,⁹ Martha Zeiger,⁹ Electron Kebebew,¹⁰ Eric Sherman,¹¹ Ronald Ghossein,¹² James A. Fagin,¹ and Timothy A. Chan^{1,3,13,*}

56 carcinomes oncocytaires (HCC)

mutations

fusions

Gains et pertes
chromosomes

épigénétique

expression

ADN mitochondrial

Données histologiques

24 = invasion minime : < 4 emboles vasculaires

32 = invasion majeure : ≥ 4 emboles vasculaires

Données cliniques

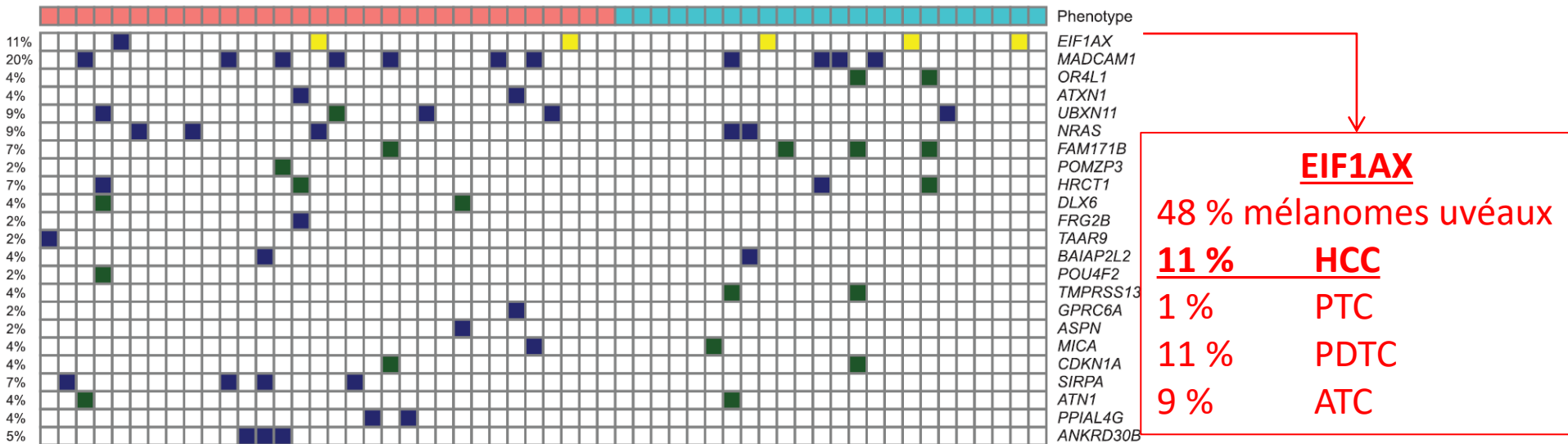
56 carcinomes oncocytaires

Mutations

- Charge mutationnelle **2.6/Mb** = cancer ovaire, glioblastome > cancer papillaire (**0.41/Mb**)
- Pas mutation BRAF, NRAS plus faible
- Gènes PDTC ou ATC présents mais moins fréquents

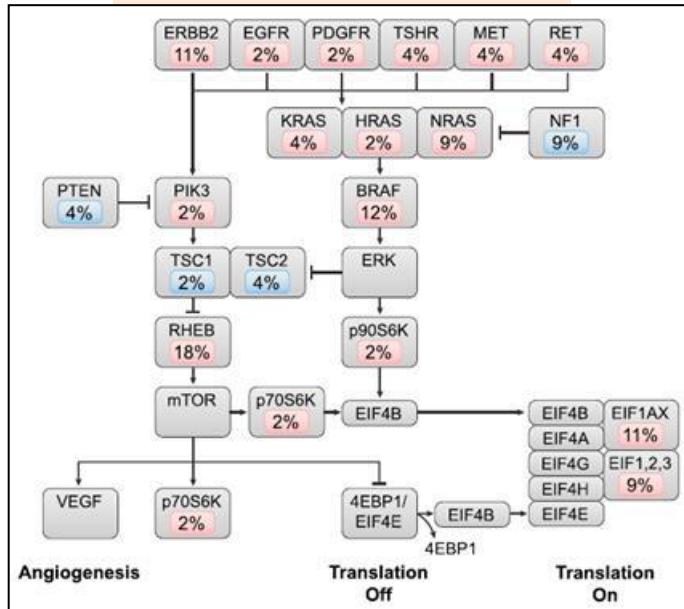
23 gènes mutés significativement
11 + fréquents

- Traduction protéique
- Signalisation
- Cytosquelette

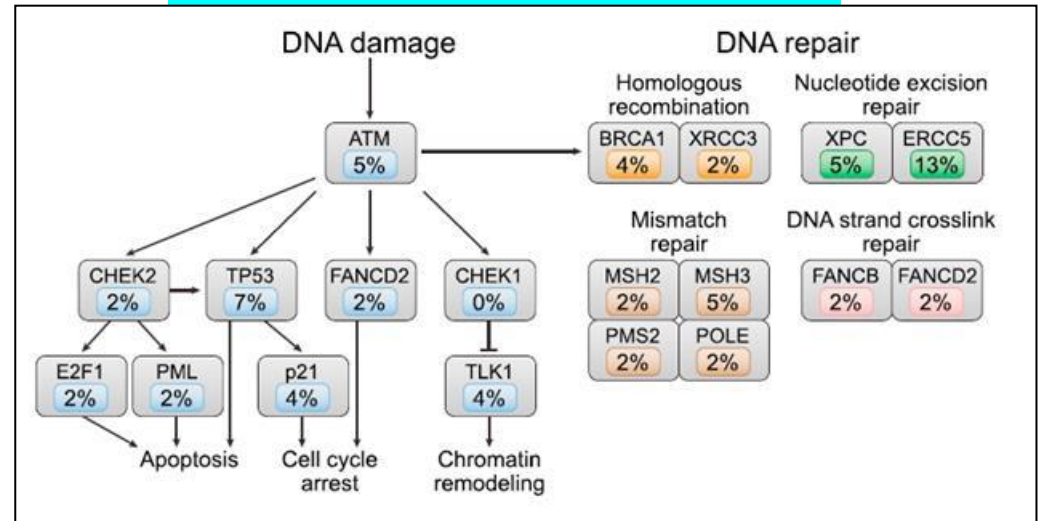


MAPK-PI3K : 55 % tumeurs

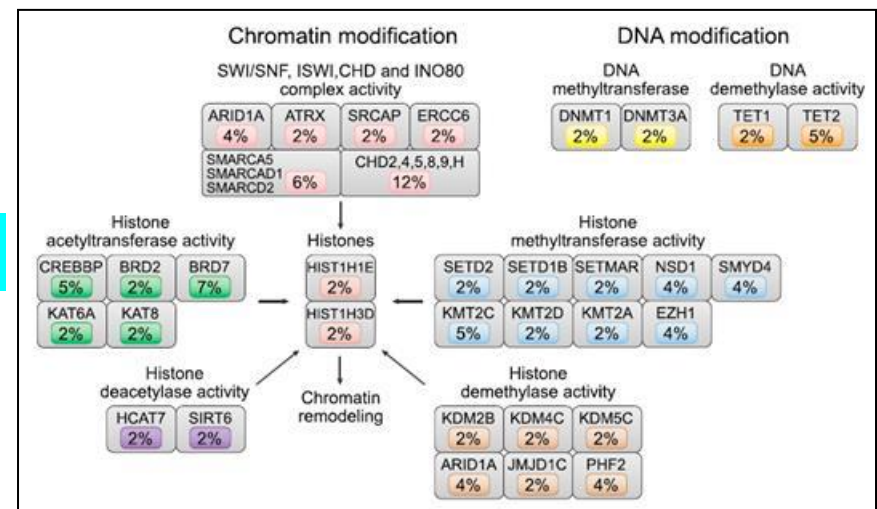
Mutation RTK = 20 %



Réparation ADN : 38 % tumeurs



Epigénétique: 59 % tumeurs



ADN mitochondrial

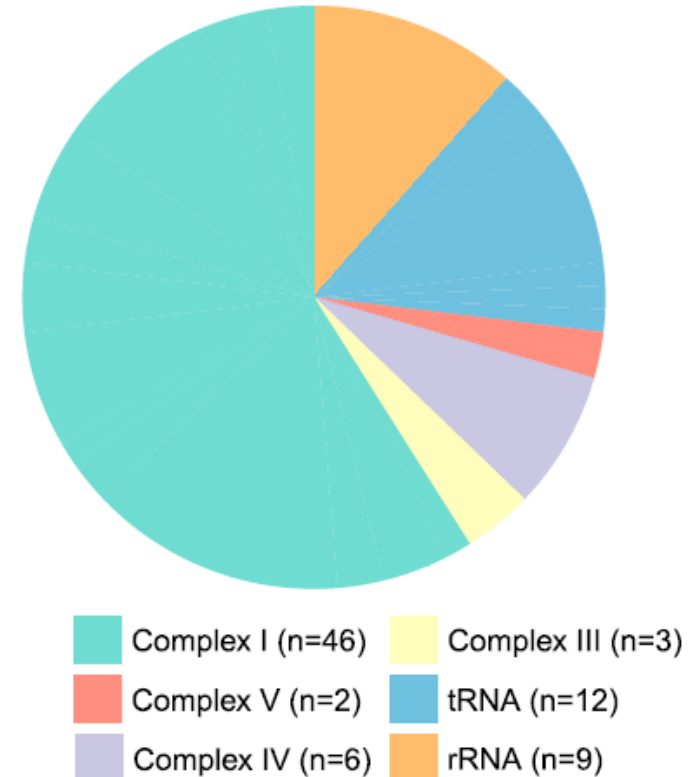
Mitochondries= nombreuses !
Dysfonctionnent !
Pourquoi ?

Mutation ADN mitochondrial =

- Une mutation 71%
- Deux mutations 24 %
- 37%= inactivation chaine respiratoire mitochondrie

Mutation ADN nucléaire-protéine mitochondrie

17 tumeurs avec mutation



Biologie moléculaire cancers oncocytaires thyroïdiens

Taux élevé mutations mitochondriales

Sources des données	Types histologiques	Non synonymous mutations (%)	Loss-of-function mutations (%)
TCGA	Classical PTC	26,8	14,8
	Follicular variant PTC	25,4	12,7
MSKCC	CMT	4	0
	PDTC	10,8	2,1
	ATC	20,4	9
Cancer Cell	HCC	71,4	36,8

Gains et pertes chromosomes

Invasive minime

- Tranquille
- diploïde

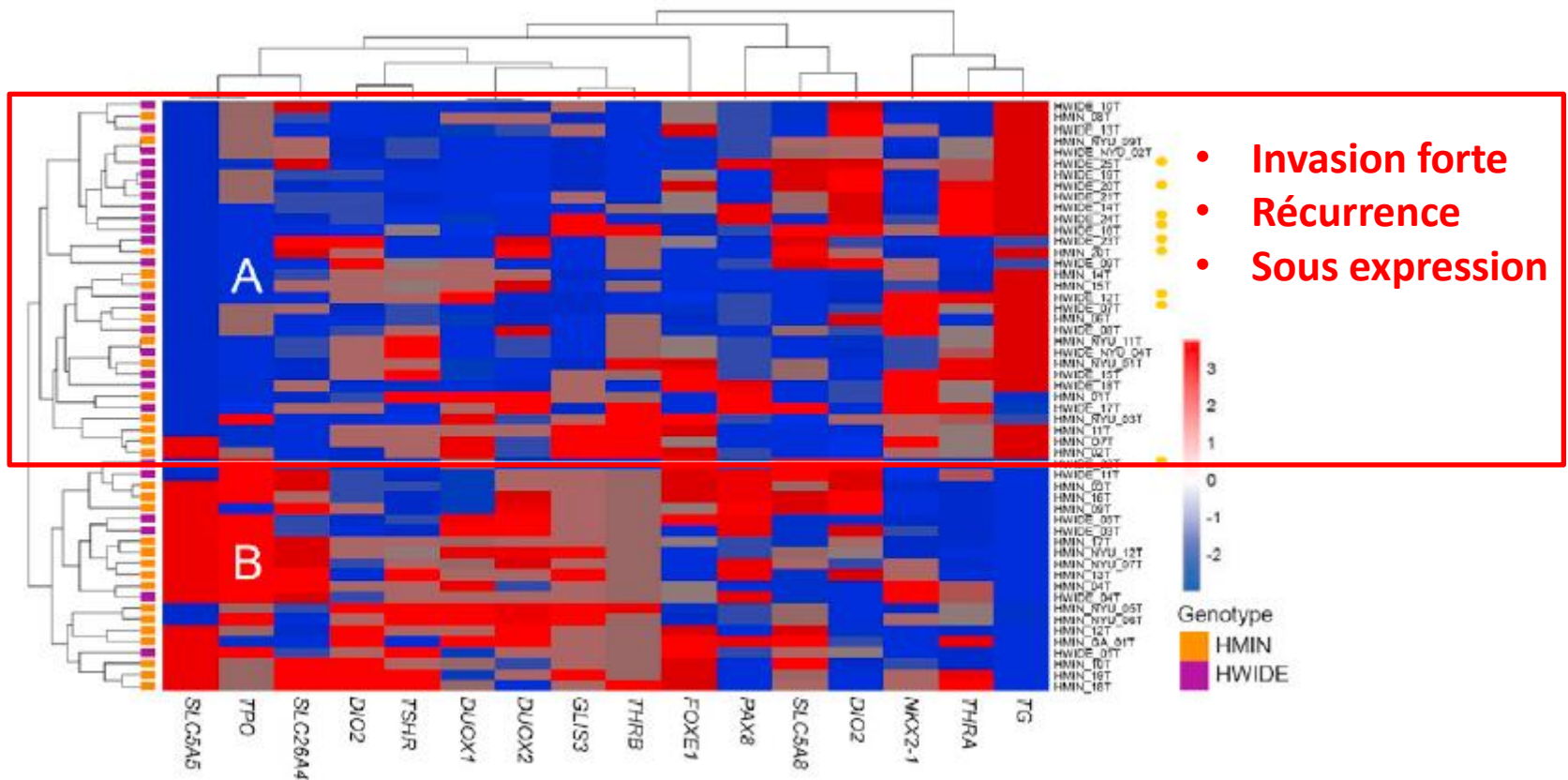
Invasive forte

- Duplication 7 quasi constante
- Parfois duplication 5 et 12
- Perte moitié chromosomes et duplication

56 carcinomes oncocytaires

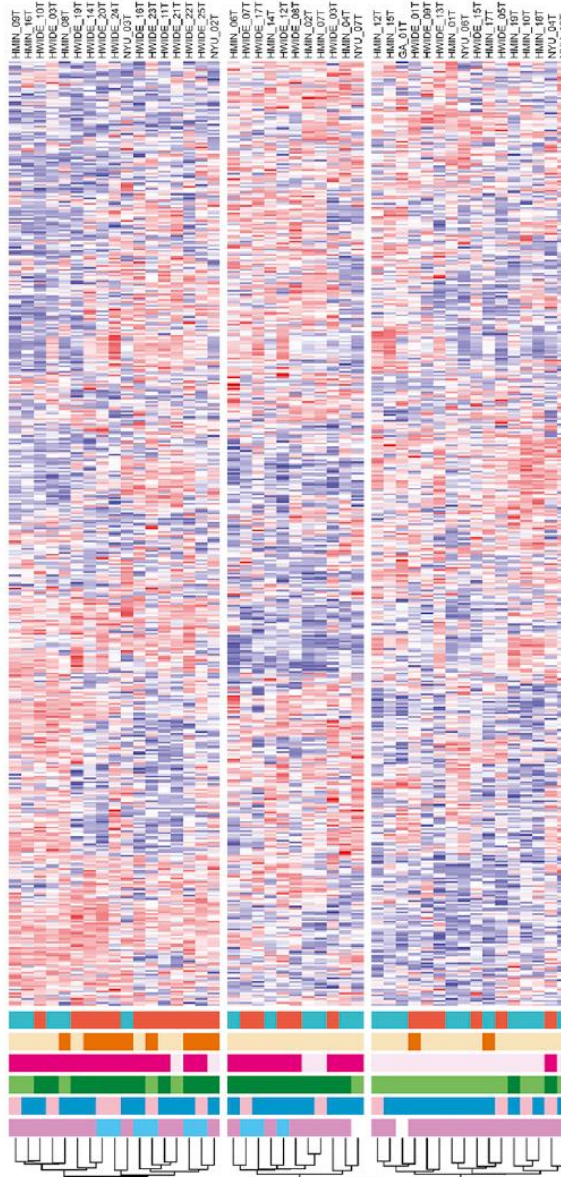
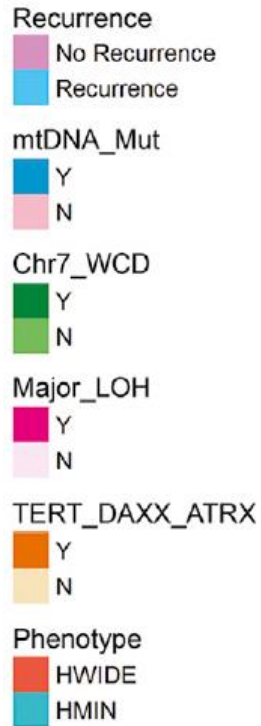expression

Analyse 16 gènes de différenciation thyroïdienne
2 groupes A et B



56 carcinomes oncocytaires

Analyse intégrée, non supervisée



Groupe 1	Groupe 2	Groupe 3
Invasif ++ TERT + LOH ++ Chr 7 ++ récidive	Invasif + LOH ++ Chr 7 ++ récidive	mimine Récidive -

Conclusion-perspectives

❑ Cancers **anomalies moléculaires spécifiques**

- **Mitochondrie**
- **WCD (Whole chromosome duplication)- oncogènes ?**
- **UPD (uniparental disomy)- gènes suppresseur tumeurs ?**
→ **histo-pronostic**

❑ **RTK/RAS/RAF/MAPK + PI3K/AKT/mTOR → traitement ?** **Sorafenib + everolimus**

Merci pour votre attention

Randomized phase II study of sorafenib with or without everolimus in patients with radioactive iodine refractory Hürthle cell thyroid cancer (HCC) (Alliance A091302/ITOG 1706).

[Eric Jeffrey Sherman](#), [Nathan R. Foster](#), [Yungpo Bernard Su](#), [Ardaman Shergill](#), [Alan Loh Ho](#), [Bhavana Konda](#), [Ronald A Ghossein](#), [Ian Ganly](#), [Gary K. Schwartz](#) Memorial Sloan Kettering Cancer Center, New York, NY; Division of Biomedical Statistics and Informatics, Mayo Clinic, Rochester, MN; Nebraska Cancer Spclsts, Omaha, NE; The University of Chicago, Medical and Biological Sciences, Chicago, IL; Division of Medical Oncology, Department of Internal Medicine, The Ohio State University Comprehensive Cancer Center, Columbus, OH; Columbia University Irving Medical Center, New York, NY

6076

Background: HCC is a rare subtype of follicular cell thyroid cancer that has been poorly studied in the past. Recent genomic studies have shown the PI3K/Akt/mTOR pathway is frequently altered in HCC. In addition, a phase II study of sorafenib (S) and everolimus (E) showed promising data in HCC. A study to evaluate this was initiated through Alliance and the International Thyroid Oncology Group. **Methods:** Patients (pts) were randomized to either sorafenib and everolimus (SE) vs. sorafenib alone (S). Inclusion criteria included; (1) diagnosis of HCC (confirmed through central review), no prior S or E, refractory to radioactive iodine, progressive disease by RECIST over prior 14 months. Primary endpoint was a comparison of progression-free survival (PFS) between SE and S using a stratified 1-sided log-rank test with 0.20 significance level and a power of 80%. 28 events were needed at final analysis. Secondary endpoints consisted of overall survival (OS), confirmed response rate (RR), and adverse events. **Results:** 35 pts were randomized from 10/2014 to 9/2019, 34 of which were evaluable for analysis (17-SE; 17-S) because 1 patient cancelled prior to receiving treatment. Median age was 66.5 years and 74% were male. ECOG performance status (PS) was 0 (47%) and PS 1 (53%). 41% had prior systemic treatment for HCC. No significant differences in baseline characteristics were observed between treatment arms. Median follow-up in 22 alive patients was 39.2 months (range: 15.1-64.9). Seven (21%) patients remain on treatment. PFS was significantly improved in the SE arm as compared to the S arm (HR=0.65 (95% CI: 0.26, 1.57); median PFS: SE=24.7 months (95% CI: 6.1-no upper), S=10.9 months (95% CI: 5.5-no upper); stratified 1-sided p=0.1662). OS was similar between the arms (2-sided p=0.4138). Confirmed response rate was similar between arms as well (SE: 18% (3 partial response (PR) vs. S: 24% (3 PR, 1 complete response)); Fisher's exact p=1.00). Grade 3 adverse event (AE) rates (regardless of attribution) were similar between arms (SE: 77% vs. S: 77%; p=1.00). Each arm had 1 patient with at least one grade 4 AE (SE patient: cardiac arrest, tracheal obstruction, encephalopathy; S patient: mucositis oral) and no grade 5 AEs. **Conclusions:** PFS was improved with the addition of E to S in this small randomized multi-institutional phase II study done. Accrual was difficult, but these promising results suggest that this combination should be further studied. Support: U10CA180821, U10CA180882, U24CA196171; <https://acknowledgments.alliancefound.org>; Novartis/GSK; ClinicalTrials.gov Identifier: NCT02143726. [Clinical trial information: NCT02143726](#).